

Spine

Targeted percutaneous transforaminal endoscopic discectomy in 295 patients: comparison with results of microscopic discectomy

Myung-Jin Kim, MD^a, Sun-Ho Lee, MD^{b,*}, Eul-Soo Jung, MD^a, Byong-Gil Son, MD^a, Eun-Seok Choi, MD^a, Jong-Hyun Shin, MD^a, Joo-Kyung Sung, MD^b, Yong-Chul Chi, MD^a

^aDepartment of Neurosurgery, Bogang Spine Hospital, Daegu, Republic of Korea

^bDepartment of Neurosurgery, Kyungpook National University, School of Medicine, Daegu, Republic of Korea

Received 5 July 2006; accepted 13 December 2006

Abstract

Background: The aim of this study is to compare the clinical outcomes and complications after targeted PTED and conventional microscopic discectomy for removing 1-level unilateral LDH and to evaluate the efficacy of PTED for the treatment of LDH.

Methods: The authors retrospectively examined 915 consecutive patients who underwent PTED (group A, 301 patients) and microscopic discectomy (group B, 614 patients) for 1-level unilateral LDH. Patients who were treated with a discectomy in the period from July 2003 to December 2004 were evaluated by telephone interview and institute visit. This assessment was performed at least 18 months (range, 18–36 months) after their operation. The follow-up rate in groups A and B was 97.5% (295 patients) and 96.5% (607 patients), respectively.

Results: Good or excellent results were obtained in 84.7% and 85.0% of groups A and B ($P = .92$). The rates of recurrence were 6.44% and 6.75% in groups A and B ($P > .05$). Twenty-eight patients (14 cases of recurrence, 5 cases of incomplete removal, 5 cases of stenosis, 2 cases of diskogenic back pain, and 2 cases of diskitis) in group A and 38 patients (26 cases of recurrence, 6 cases of incomplete removal, 2 cases of stenosis, 2 cases of diskogenic back pain, 1 case of hematoma, and 1 case of diskitis) in group B underwent reoperation.

Conclusions: Based on our results, the PTED can be a reasonable alternative to a conventional microscopic discectomy for the treatment of patients with LDH, except for those in downward far-migrating cases beneath the pedicle of the lower vertebra or in cases involving L5-S1 with a high pelvis.

© 2007 Elsevier Inc. All rights reserved.

Keywords:

Transforaminal; Endoscopic; Microscopic discectomy; Comparison

1. Introduction

The surgical treatment of LDH has evolved considerably since Dandy reported the first cases in 1929 [5]. In 1978, Williams [28] described the concept of microscopic discectomy, which became the criterion standard of surgical treatment of LDH so far [1]. Minimal invasive surgical techniques for various spinal pathologies are under develop-

ment, and many spinal surgeons have been interested in the percutaneous approach for management of LDH [7,9,10,12,14–17,21,22,24]. Since the introduction of the arthroscope for herniated disk removal, various procedures for percutaneous endoscopic discectomy have been described in cases of mild herniation (contained and small subligamentous disk herniation) [11,15]. Noncontained and migrating LDHs have been considered contraindications for this procedure because of the restricted surgical field [7,8,20–23], although a few reports have suggested that PTED may be a valuable method for these as well [15,25–27].

Recently, as endoscopic instruments and techniques have developed, it has become possible to perform selective and targeted fragmentectomy with direct visualization of the

Abbreviations: AP, anteroposterior; CT, computed tomography; LDH, lumbar disk herniation; MR, magnetic resonance; PTED, percutaneous transforaminal endoscopic discectomy; YAG, Yttrium aluminum garnet.

* Corresponding author. Tel.: +82 53 420 5649; fax: +82 53 423 0504.

E-mail address: sobotta@dreamwiz.com (S.-H. Lee).

pathological lesion and neural structures [20,25–27]. Some reports suggested that PTED could be widely used for most LDHs, with comparable clinical outcomes to those of conventional open surgery [16,27].

Here we presented the surgical outcomes and complications of 902 patients with LDH who underwent targeted PTED or conventional microscopic discectomy for LDH and compared the efficacy of targeted PTED as a standard treatment of LDH with that of microscopic discectomy.

2. Materials and methods

2.1. Patient population

The general inclusion criteria for surgical intervention required clinical evidence of disk herniation at 1 disk level from L1 to S1 and 3 to 6 weeks of conservative treatment that failed to improve major motor weakness, intractable leg pain, and functional impairments. All patients included in this study had intractable radicular symptoms such as sciatica, a positive straight-leg raising test, and sensory and/or motor disturbances. This study included unilateral intracanal and foraminal soft herniations of 1 level. The cases with recurrent herniation and far lateral herniation and those with incomplete fragment removal after previous surgical intervention at the index level, spinal stenosis, and segmental instability including spondylolisthesis were excluded from the study group.

According to these criteria, a retrospective review was performed on 301 consecutive patients who underwent PTED (group A) and 614 patients who underwent conventional open microscopic discectomy (group B) for 1-level unilateral LDH in the period from July 2003 to December 2004. Two authors (MJK, BGS) performed PTED as the treatment method in 301 consecutive patients

with contained, noncontained, or migrating L1 to S1 LDHs. The other authors performed a microscopic discectomy only on 614 patients during the same period. The inclusion criteria of PTED met the objective indications for the conventional open microdiscectomy procedure. In contrast, we limited the exclusion criteria of PTED to downward high-grade migrating disk cases and some cases involving L5-S1 with a high pelvis because we could not access the affected region with PTED. The average period from symptom initiation to index surgery was 10.8 weeks.

2.2. Surgical techniques in targeted PTED

Percutaneous transforaminal endoscopic discectomy was performed with the patient under local anesthesia; the patient was placed in the knee-chest prone position on a radiolucent table with mild flexion of the back. We used the Yeung Endoscopic spine system (Richard Wolf Surgical Instrument Co, Vernon Hills, Ill), which was reported by Yeung [26]. The procedure was performed after the patients had received local anesthesia and intravenous sedation to minimize anxiety or discomfort and to allow continual feedback during the procedure. The entry site on the trajectory line was determined according to the location of the disk herniation. The entry point was also estimated from abdominal CT, which provides precise planning and safety, and is generally 10 to 14 cm from midline (Fig. 1). In the case of a contained and paracentral LDH, a long 18-gauge spinal needle was inserted from the entry point toward the medial pedicular line in the AP view under fluoroscopic guidance. Otherwise, in cases of noncontained or migrated herniation, the entry site was further lateral than that of the contained case (Fig. 1). The needle tip was positioned at the medial pedicular line in the AP projection and on the posterior vertebral line in the lateral projection (Fig. 2A and B). After inserting the needle, an epidurogram was performed with 3 mL of contrast media (Fig. 2C). At this time, a transforaminal epidural infiltration with 1% lidocaine is recommended to prevent approach-related pain and discomfort. After confirming the exiting and traversing root, a needle was advanced to the center of the disk and intraoperative diskography was performed using a mixture containing 9 mL of contrast media and 1 mL of indigo carmine. The pathologically degenerated nucleus and annular fissure can then be stained for easy discrimination through both the fluoroscope and endoscope.

After performing a diskography, a guide wire was advanced through the needle channel until the tip had reached the center of the disk space on the AP projection; and then the spinal needle was removed. After making a 6- to 7-mm-long skin incision, an obturator was passed over the guidewire to near the medial margin of the pedicular line on the AP view, at which time the posterior annular surface was reached and further advanced to the center of the disk by gentle hammering (Fig. 2D). A 6-mm-diameter working cannula with an oblique window was advanced over the obturator (Fig. 2E).

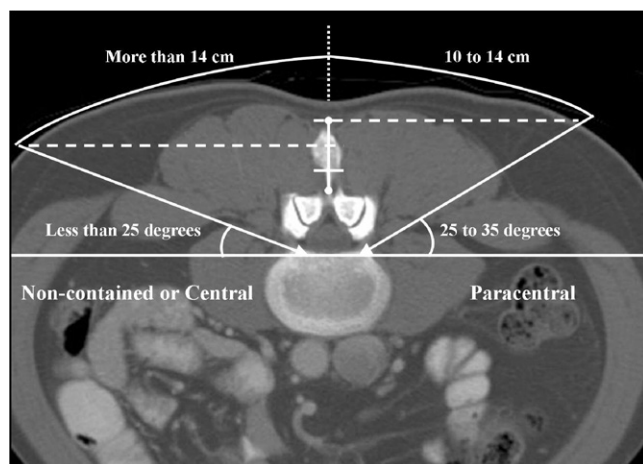


Fig. 1. The disk level on the L4-5 segment in the axial of abdominal CT. The entry point and angle were calculated from the abdominal CT. The entry site and angle on the trajectory line are dependent on the location of the herniation and the level of obesity in the patients. It is generally 10 to 14 cm from the midline in cases of paracentral herniation. The approaching angle of the spinal needle is 25° to 35°.

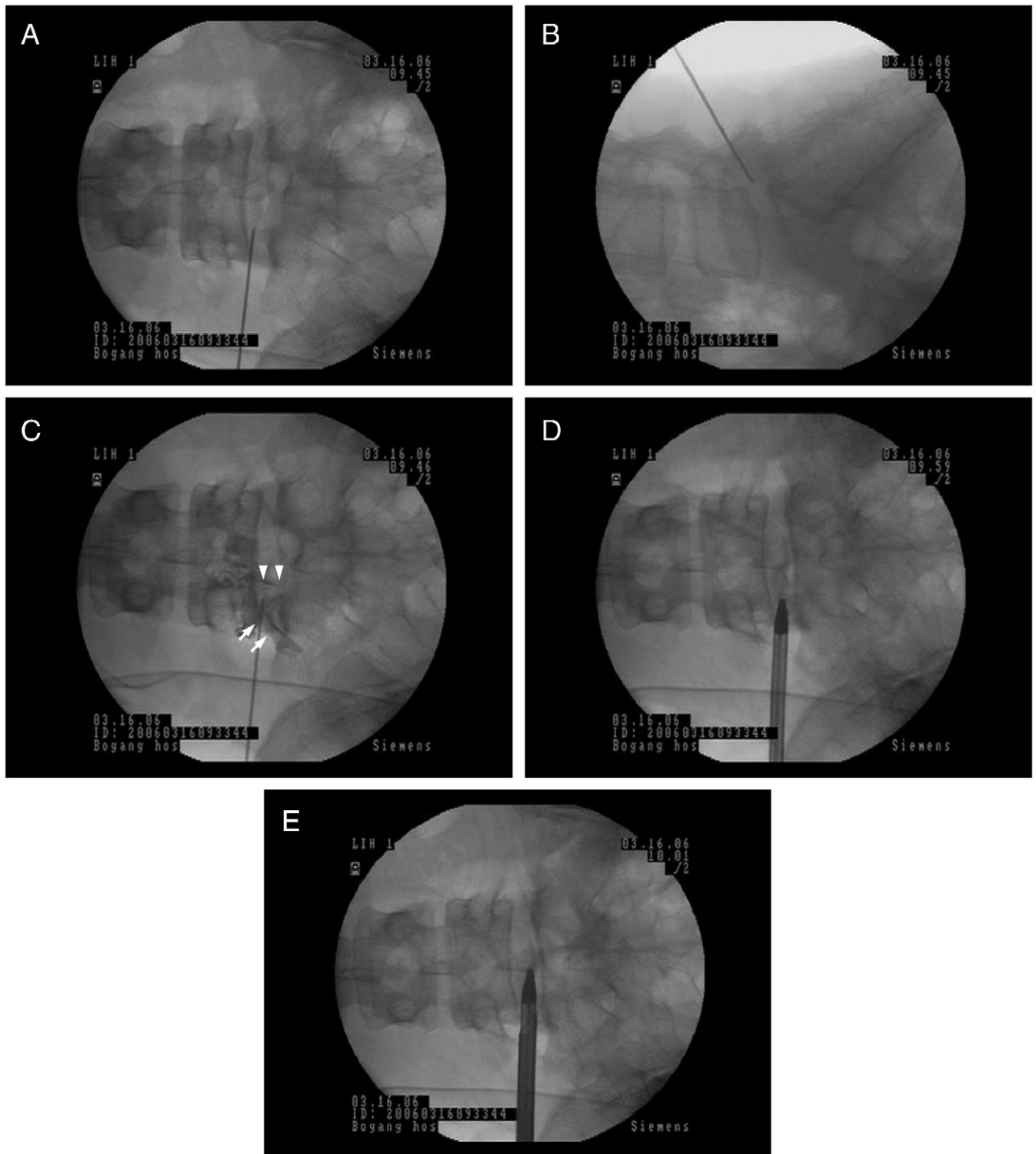


Fig. 2. The surgical procedure of noncontained LDH from the fluoroscopic view. A: This image shows the AP view when the guide needle is positioned at the medial pedicular line. B: Lateral view when the guide needle is positioned at the posterior vertebral line on the lateral view. C: AP view after an epidurogram (white arrow, exiting nerve; arrowhead, traversing nerve). D: The needle was replaced by a guide wire followed by an obturator and a final working cannula in that sequence (E).

An endoscope was introduced through the working cannula after removing the obturator. Discectomy was performed as a standard approach to LDH after insertion of endoscope. In the endoscopic view of most cases, the

degenerated disk materials, which were stained bluish by indigo carmine, could be observed and removed under direct visualization (Fig. 3A). Sometimes, it was also useful to release annular tissue around the herniated disk to

generate enough working space to move the endoscopic instrument. Sometimes, to gain access to the herniated fragment, the sidewalls of the annular fissure were widened using a side-firing holmium-YAG laser and a bipolar radiofrequency coagulator (Ellman; Ellman International, Hewlett, NY). After a sufficient annulectomy, blue-stained herniated fragments could be observed. After decompress-

ing the lesioned disk space, the epidural fat tissue and traversing root could be well visualized; and the deeper portion of intraspinal canal was examined by advancing the endoscope under the traversing root and dura (Fig. 3B). Finally, the intradiskal decompression was performed around the lesion site.

Using this approach and technique, we could access the ventral dura and remove the extruding disk easily in the epidural space. In cases of disk migration, we could move the working cannula to the cephalic or caudal portion of the epidural space under direct visualization and obtain enough space to reach the migrating portion by angulation of the cannula in that direction. A large migrated disk material and a small fragment were found between the ventral dura and dorsal vertebral body. These were removed successfully using an endoscopic forceps and a dissector (Fig. 3C).

After removing the endoscope, a 1-point stitch was performed and a sterile dressing was applied. During the whole procedure, the amount of blood loss was minimal (less than 1–5 mL). The patients were generally discharged the next day after surgery if there were no postoperative problems.

2.3. Assessment of clinical outcome

The evaluation was performed in a surgeon-independent manner at least 18 months after the index operation. The clinical material available for evaluation included all information submitted according to the predetermined surgical protocol. The clinical material included preoperative history and physical examination, operating notes, image studies, intraoperative videotapes, and laboratory reports. The postoperative data included follow-up, telephone interviews, and any revisions as the clinical situation required. Results were determined to be excellent, good, fair, or poor according to the MacNab criteria [19]; and a *successful outcome* was defined as excellent or good based on our criteria (Table 1). Follow-up examinations were carried out on postoperative day 1, then after 1, 3, and 6 months and every 12 months. Statistical analysis was performed using Student *t* test, χ^2 test, and Fisher exact test, with 2-tailed *P* values less than 0.05 considered significant.

3. Results

Among 301 patients who underwent PTED, 295 patients were evaluated through follow-up (group A). There were 188 (63.7%) male and 107 (36.3%) female patients with a mean

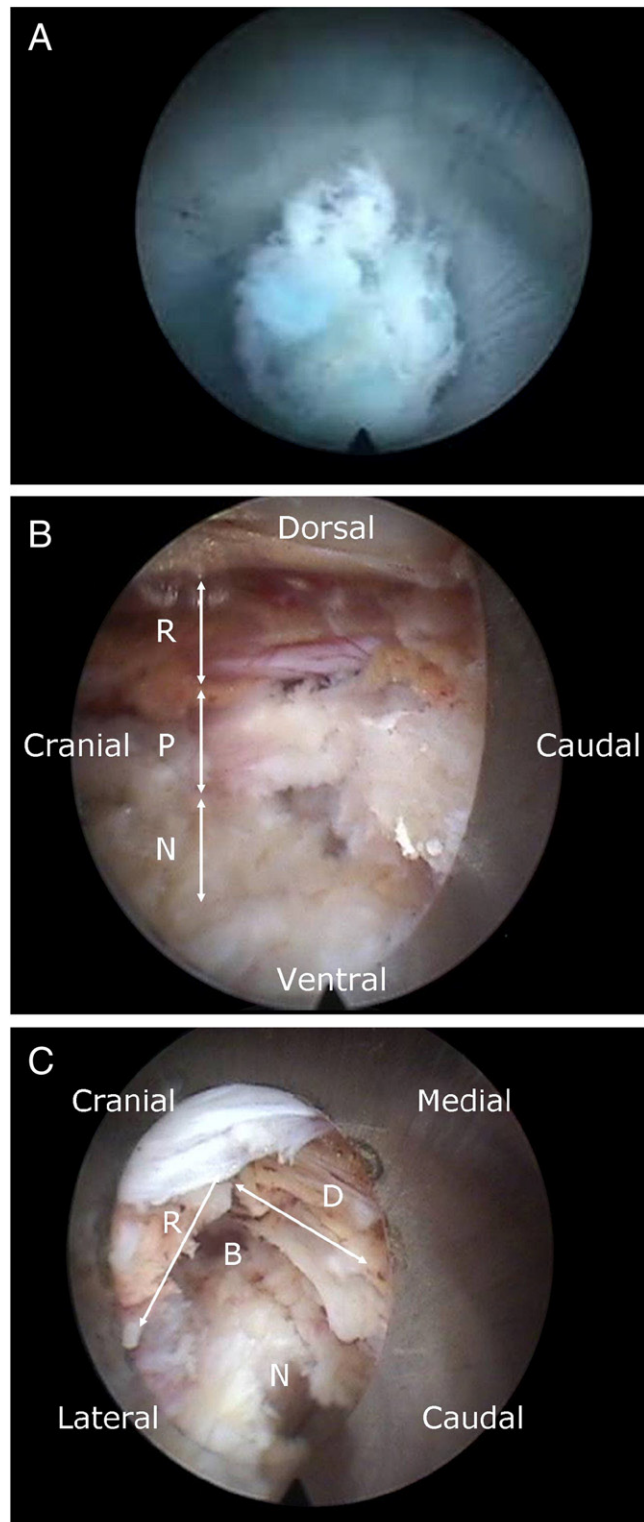


Fig. 3. Intraoperative endoscopic view. A: The degenerated disk materials, which were stained bluish by indigo carmine, could be observed and removed under direct visualization B: After the adequate removal of the disk, the anatomical details are well demonstrated, including the traversing root (R), posterior longitudinal ligament (P), and the remaining nucleus pulposus (N). C: In the case of an upward migrating disk, enough space was obtained to reach the migrating portion by the angulation of the cannula in that direction. A migrated disk material and fragment were found between the ventral dura (D) and dorsal vertebral body (B). Exiting root (R) surrounding epidural fat tissue was visualized.

Table 1
MacNab criteria

Classification	Criteria
Excellent	No pain; no restriction of activity occasional
Good	Back or leg pain of sufficient severity to interfere with the patient's ability to do normal work or capacity to enjoy leisure hours
Fair	Improved functional capacity, but handicapped by intermittent pain of sufficient severity to curtail or modify work or leisure activity
Poor	No improvement or insufficient improvement to enable increase in activities; further operative intervention required

age of 34.9 years (range, 13–83 years). The levels of disk herniation were L1–2 (3 cases), L2–3 (3 cases), L3–4 (17 cases), L4–5 (191 cases), and L5–S1 (81 cases). In group B, 607 of the initial 614 patients (392 men, 64.6%; 215 women, 35.4%) with a mean age of 44.4 years (range, 17–80 years) were evaluated through follow-up. The levels of disk herniation were L1–2 (4 cases), L2–3 (16 cases), L3–4 (32 cases), L4–5 (362 cases), and L5–S1 (240 cases). The follow-up rate was 97.5% in group A and 96.5% in group B. The average follow-up period was 23.6 months (range, 18–36 months). The demographic characteristics are summarized in Table 2.

3.1. Comparisons of clinical outcome

The results for these 2 groups are shown in Table 3. Based on the MacNab criteria, the surgical outcomes were rated as follows: (1) Group A—Out of 295 patients, 140 had excellent results, 110 had good results, 29 had fair results, and 16 had poor results. Of the 29 fair results, 5 patients had stenosis, 12 had recurrence, and 2 had diskogenic back pain. In the 16 poor cases, 7 recurrences, 7 with incomplete extirpation of disk, and 2 with diskitis were included. (2) Group B—Out of 607 patients, 290 had excellent results, 226 had good results, 51 had fair results, and 40 had poor

Table 2
Demographic summary in 295 patients of PTED and 607 patients of microscopical discectomy for treatment of LDH

Parameter	Procedure	
	Group A (PTED)	Group B (microdiscectomy)
No. of cases	295	607
Sex (M: F)	188:107	392:215
Age (y)	34.9 (13–83)	44.4 (17–80)
<20	22	19
20–29	70	108
30–39	71	150
40–49	65	121
50–59	36	107
> 60	31	101
Level of surgery (%)		
L1–2	3 (1.0)	4 (0.7)
L2–3	3 (1.0)	17 (2.2)
L3–4	17 (5.8)	32 (5.4)
L4–5	191 (64.7)	325 (57.2)
L5–S1	81 (27.5)	229 (34.4)

Table 3
Clinical outcome and surgical-related complication of 902 follow-up patients

	PTED (n = 295)	Microdiscectomy (n = 607)	P
Clinical outcome			
Excellent (cases)	140	290	
Good	110	226	
Fair	29	51	
Poor	16	40	
Success rate	84.7	85.0	NS ^a
No. of poor outcome (%)	45 (15.3)	91 (15.0)	NS ^a
Operation time (min)	53.0 ± 13.0	64.6 ± 28.7	<.001 ^b
No. of surgical complication (%)	9 (3.05)	10 (1.98)	NS ^c
Dural tear	3	6	
Dysesthesia	4	2	
Diskitis	2	2	
Wound infection	—	1	
Hematoma	—	1	
No. of reop (%)	28 (9.5)	38 (6.3)	NS ^c

The data are expressed as the mean ± standard deviation. Reop indicates reoperation; NS, not significant.

^a Statistical significance test was done by the χ^2 test.

^b Statistical significance test was done by the *t* test.

^c Statistical significance test was done by the Fisher exact test.

results. Of the 51 fair results, 8 patients had stenosis, 19 patients had recurrence, and 19 patients had lumbar back pain of unknown origin. In the 40 poor cases, 22 recurrences, 1 severe diskogenic back pain, 1 stenosis, and 3 diskitis were included. The rates of recurrence were 6.44% in group A and 6.75% in group B; there was no significant difference between these rates ($P > .05$). In total, the percentages of successful outcomes, with excellent or good results, were 84.7% for group A and 85.0% for group B ($P > .05$). The percentages of *unsuccessful results* (defined as failed back surgery syndrome), which included fair and poor results, were 15.3% for group A and 15.0% for group B. The causes of failed back surgery syndrome are described in Table 4. Both groups had negligible blood loss that had no significant clinical influence. Mean operative time (\pm standard deviation) was 53.7 ± 11.3 minutes in group A and 65.2 ± 19.5 minutes in group B ($P > .01$).

Table 4
Cause of the unsuccessful outcome in both groups

Cause	PTED (%) n = 295	MD (%) n = 607	P
Recurrence	19 (42.2)	41 (45.1)	NS ^a
Residual disk	7 (15.6)	6 (6.6)	.102 ^a
Lateral stenosis	5 (11.1)	9 (9.9)	NS ^b
Diskogenic LBP	2 (4.4)	2 (2.2)	NS ^b
Neuropathic pain	4 (8.9)	2 (2.2)	.093 ^b
Unknown LBP	6 (13.3)	27 (29.7)	.07 ^a
Diskitis and infection	2 (4.4)	3 (3.3)	NS ^b
Hematoma	—	1 (1.1)	—
Total	45	91	NS ^a

MD indicates microscopical discectomy; NS, not significant; LBP, lumbar back pain.

^a Statistical significance test was done by the χ^2 test.

^b Statistical significance test was done by the Fisher exact test.

Table 5
Cause of and procedure for the reoperation

	No. of cases (type of revision)	
	PTED	Microscopic discectomy
Recurrence	14 (P:3, M:7, F:4)	26 (P:2, M:9, F:15)
Residual disk	5 (M:5)	6 (M:6)
Stenosis	5 (F:5)	2 (F:2)
Diskogenic LBP	2 (F:5)	2 (F:2)
Diskitis	2 (P:1, E:1)	1 (E:1)
Hematoma	—	1 (E:1)
Total	28	38

P indicates percutaneous transforaminal endoscopic discectomy; M, microscopic discectomy; F, fusion surgery; E, exploration only.

3.2. Surgical complications and reoperation

Nine patients in group A and 12 patients in group B had surgical complications related to the operation. The rate of surgical complication was 3.05% in group A and 1.98% in group B. There was postoperative dysesthesia in 4 and 2 patients in groups A and B, respectively. There were no deaths and no intraoperative vascular injuries (Table 3).

In all, 28 patients in group A (14 cases of recurrence, 5 cases of incomplete removal, 5 cases of stenosis, 2 cases of diskogenic pain, and 2 cases of diskitis) and 38 patients in group B (26 cases of recurrence, 6 cases of incomplete removal, 2 cases of stenosis, 2 cases of diskogenic pain, 1 case of hematoma, and 1 case of diskitis) underwent reoperation (Table 5). The rate of reoperation was 9.5% in group A and 6.3% in group B. There were no significant differences in the rates of surgical complications and reoperation between the 2 groups.

4. Discussion

Although the concept of posterolateral percutaneous lumbar disk decompression was first introduced by Kambin in 1973 [14], more than a quarter of a century later, endoscopic lumbar spine surgery is still limited to a small number of surgeons because of several technical challenges presented by the posterolateral endoscopic procedure. First, safe and effective access is limited to a narrow channel. Second, there is little or no working space, as compared

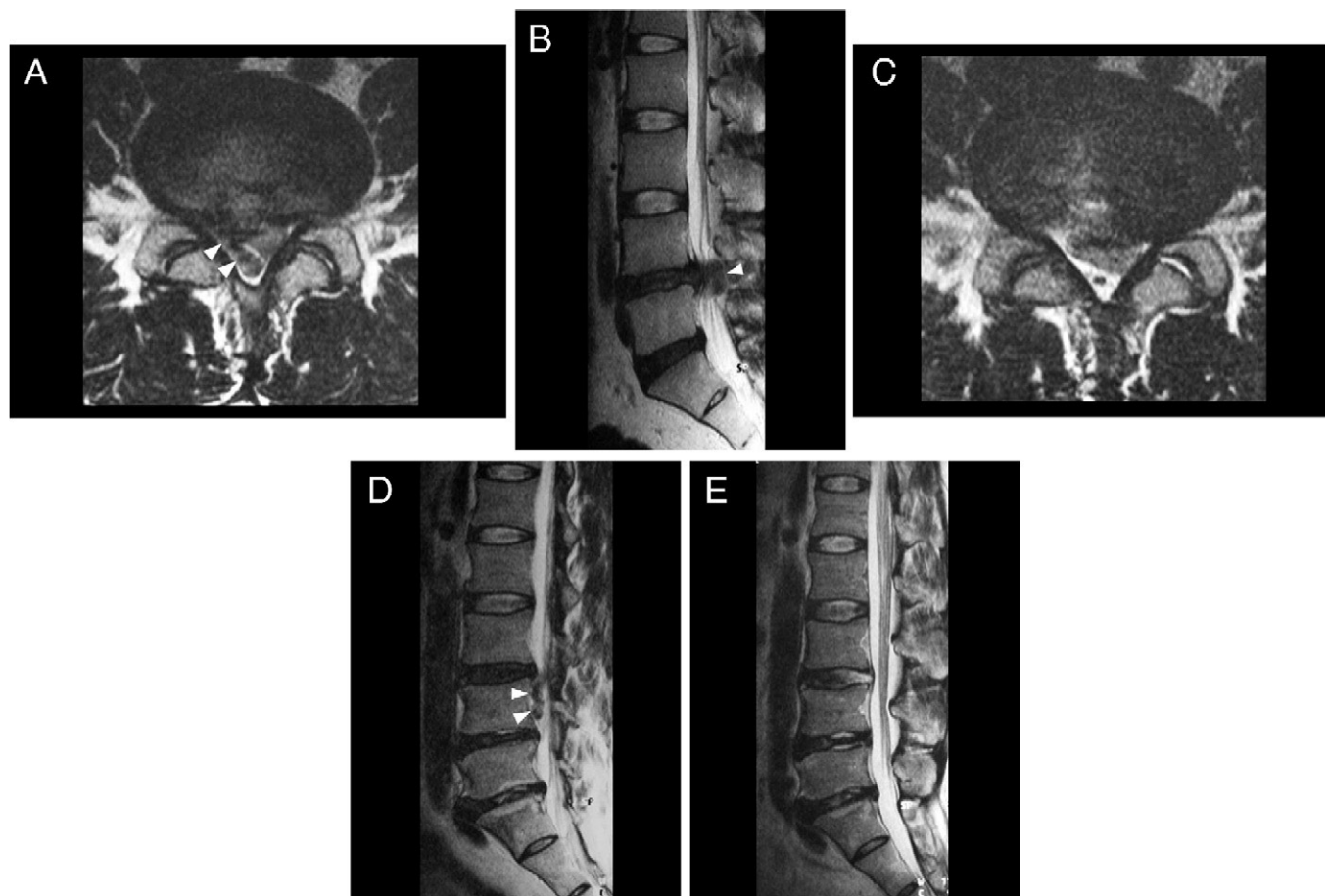


Fig. 4. Case illustrations. A and B: A 36-year-old man with severe right leg pain and weakness of dorsiflexion on ankle and great toe, caused by severe, noncontained, LDH on L4-5, was treated with PTED. C: Postoperative MR images show complete removal of extruded material. D: A 50-year-old man with right buttock pain and weakness of knee extension, caused by downward migrating lumbar disk on L3-4, was also treated with PTED. E: Postoperative T2-weighted sagittal MR images show removal of migrating disk. White arrowheads indicate herniated disk.

with conventional open surgery. Third, creation of an intradiskal work space is needed before intracanal disk fragment extraction. Fourth, a herniated fragment is accessible only when the operating instrument is placed in the optimal trajectory [27].

Since Yeung introduced a rigid rod lens, integrated, multichannel, wide-angle operating spinal endoscope [25–27], the available data indicate that the PTED technique is versatile and safe. A bevel-ended tubular-access cannula allows same-field viewing of the epidural space, annular wall, and intradiskal space. The various tissues—disk, bone, ligament, fat, vessel, nerve, and dura—are readily identifiable under the endoscope. Although it was widely accepted that the L5-S1 disk space and large herniations were generally inaccessible before the advent of endoscopic visualization [4,12–15], recent adaptations allow surgeons a wide-angle view of the surgical field and decompression of nerve roots under direct vision through a single portal in most cases. In 295 of the consecutive cases of LDH using targeted PTED, the authors evaluated surgical technique, outcome, and complications retrospectively. The series included both noncontained and foraminal herniations. There were no exclusions for technique-related reasons. The authors' experience with the lumbar posterolateral transforaminal endoscopic technique indicates that most lumbar disk spaces and their adjacent epidural spaces are accessible, with the exception of some cases involving the L5-S1 disk.

4.1. Approaches for extruded and migrating disk herniation

In dealing with migrated herniations, some potential problems cause surgeons to consider the percutaneous endoscopic technique demanding. First, access through a narrow channel might be ineffective and might cause an injury to the neural structure during extraction of the migrated fragments with endoscopic forceps. Second, the mechanical ability to reach and grasp the herniated fragments lags behind the endoscope's optical capabilities [27]. Placement of the endoscope in the optimal trajectory improves the mechanical instrument's effective reach. Non-contained herniations in the epidural space require an access trajectory of 15° to 20° so that the endoscopic instrument can reach posteriorly into the epidural space (Fig. 4A–C). The surgical techniques to gain access to fragments located in the epidural space, including widening of the intradiskal working canal and a sufficient extension of the annular tear, are always necessary, too. When adequate widening of the intradiskal working cavity is achieved, the angle of the endoscope becomes more horizontal and pivots on the foramen. Thus, a surgeon can examine the full undersurface of the annulus and identify the blue-stained, epidural-located disk fragments [2].

In the anatomical aspect of the intervertebral foramen, the available angle to reach around the superior boundary of the foramen is much larger than that around the inferior boundary of the foramen. Intraoperatively, these anatomical character-

istics allowed the endoscopic instruments enough angles to go through the foramen into the upper portion of the spinal canal and to successfully and easily remove cephalad-migrated disk materials. On the other hand, in the case of caudal-migrated disk herniations, the inferior boundary of the foramen was a serious obstacle to reaching the spinal canal below the disk level; and complete removal of sequestered disk material was sometimes impossible [3]. If the fragments were not too far away from the disk space beneath the lower pedicle, however, the results of this study show that the migrated fragments were accessible with current instrument and technique in most cases (Fig. 4D and E).

4.2. Comparison of clinical outcomes

In our series, the minimal follow-up period of 18 months seems to be satisfactory for evaluating the endoscopic excision in a herniated lumbar disk. The satisfactory result rate of 84.4% in this series is comparable to the successful outcome of 85.0% in our conventional discectomy group and the 88.2% in a restricted endoscopic series by Kambin et al [15]. The satisfactory result rate of 87.3% for microscopic discectomy reported by Abernathy and Yasargil is also statistically comparable [1]. In 1993, Mayer and Brock showed that the clinical results of PTED are comparable, and in some respects superior to those of conventional microscopic discectomy [21,22]. They noted that the PTED required local anesthesia and shorter hospitalization and resulted in less tissue trauma and less epidural scarring. A study by Lew et al has shown considerably more promise, as in our series; early results obtained from their series, in which transforaminal endoscopic lumbar discectomy was performed, are similarly encouraging [18]. They reported an overall success rate of 85% (42 of 47 cases) and revision rate of 11% (5 cases).

Delamarter and McCulloch [6] reported a recurrence rate of 5% ± 2% after microscopic discectomy for LDH. The recurrence rate of 6.44% in our PTED group was comparable to that of our conventional group (6.75%) and the previous outcome data.

4.3. Surgical complications of PTED

This study had a minimal combined major and minor complications rate. There were 9 complications after percutaneous endoscopic discectomy (3.05%) and 10 complications after conventional discectomy (1.98%) in the present series. The published complication rate for endoscopic excision of LDH was also low. As a technique, many clinicians have developed a variation of the freehand, biplane, c-arm guidance method to gain posterolateral entry into the intradiskal and epidural spaces with the patient under local anesthesia. The patient, in a continuous awakened state, is instructed to alert the surgeon if there should be any inadvertent physical trauma to the nervous structures. Pain relief from adequate nerve root decompression in a conscious patient is quickly apparent in the

operating room. Should the radicular pain persist because of a missed fragment, the problem is readily identified within the immediate postoperative period.

In terms of surgical complications, our series included 4 patients in group A and 2 patients in group B who experienced transient extremity dysesthesia; the condition improved within 6 months. Besides complications due to the approach such as dysesthesia or nerve root injury, there were no significant differences in complications between the 2 groups. Choi et al proposed that heat transmission to the neural structures from a radiofrequency coagulator was the main cause of painful postoperative dysesthesia [3]. On the other hand, the mechanical compression of dorsal root ganglia by the cannula in the epidural space could be another cause of dysesthesia [4]. The patients with these complications fully recovered from their condition after conservative management including physical therapy and repeated epidural injection therapy, so these results were not subject to the mandatory poor rating rule. To decrease the risk of complications, detailed evaluation of preoperative abdominal CT images for possible variations as well as correct probe placement will provide more safety.

4.4. Reoperation of PTED and its cause

Despite the younger age of the PTED group, there was a higher revision rate (9.5%) than that of the microscopic discectomy group (6.3%). First, PTED has its own learning curve like every new technique. When the results were evaluated every sixth month, in the first 6 months, 15 reoperations (18.1%) were performed in 83 patients, and 4 of the 5 residual disks were developed in this period. However, there were only 5 (4.8%) reoperations in the 105 operated patients during the last 6 months, and there were no revisions of the residual disk. Second, we tended to underestimate the concurrent pathology of LDH in the younger patients (eg, 5 cases of stenosis). Schaffer and Kambin analyzed 11 patients who underwent reoperation out of 100 patients treated with PTED in 1991 [23]. In their analysis, the most common causes for subsequent surgery for the 11 patients were a lateral recess stenosis, sequestered herniation, and improper placement of the working instruments. With the exception of recurring or residual disk, the presence of concurrent lateral recess stenosis was the major factor predicting a poor outcome. If the hernia mass is overtly calcified or combined with severe spinal stenosis, the effect of an endoscopic removal could be limited. If there are severe neurological deficits such as cauda equina syndrome or foot drop, an open reexploration is mandatory. These results showed that PTED is safe and effective after a sufficient learning curve if the patient selection criteria are followed strictly.

4.5. Limitation of the study

Despite these outstanding results, this study had some limitations. One is the lack of surgeon standardization. This report of our PTED experience was from the data collected from 6 surgeons at a single institution. In addition, the

surgical method chosen was according to the surgeon's own preference. The lack of standardization of the study groups is another limitation of a retrospective study. Because of the possible patient selection biases of these groups, the relevant clinical significance of the surgical outcome and revision could not be investigated properly. Therefore, a further examination and future clinical study will be needed to determine the clinical effectiveness and safety of PTED.

5. Conclusions

In this study, we have demonstrated the safety and efficacy of PTED in the treatment of patients with LDH of various sites. Our success rate is comparable with that of conventional open surgical procedures. The complication and revision rates were also comparable to conventional treatment. Based on these results, PTED can be a reasonable alternative to conventional microscopic discectomy for the treatment of patients with LDH, except in downward far-migrating cases or in cases involving L5-S1 with a high pelvis.

References

- [1] Abernathy CD, Yasargil MG. Results in microsurgery. In: Watkins RG, editor. *Microsurgery of the lumbar spine*. Rockville: Aspen Publishers; 1999. p. 223–6.
- [2] Ahn Y, Lee SH, Park WM, et al. Percutaneous endoscopic lumbar discectomy for recurrent disc herniation: surgical technique, outcome, and prognostic factors of 43 consecutive cases. *Spine* 2004;29:326–32.
- [3] Choi SJ, Ji C, Ahn JG, et al. Efficacy of percutaneous transforaminal endoscopic discectomy in noncontained and extruded lumbar disc herniation. *Kor J Spine* 2004;1:107–12.
- [4] Choi G, Lee SH, Raiturker PP, et al. Percutaneous endoscopic interlaminar discectomy for intracanalicular disc herniations at L5-S1 using a rigid working channel endoscope. *Neurosurgery* 2006; 58(1 Suppl):59–68.
- [5] Dandy WE. Loose cartilage from intervertebral disc simulating tumor of the spinal cord. *Arch Surg* 1929;19:660.
- [6] Delamarter RB, McCulloch JA. Microdiscectomy and microsurgical spinal laminotomies. In: Frymoyer JW, editor. *The adult spine: principles and practice*, 2nd ed Philadelphia: Lippincott-Raven; 1997. p. 1961–88.
- [7] Ditsworth DA. Endoscopic transforaminal discectomy and reconfiguration: a posterolateral approach into the spinal canal. *Surg Neurol* 1998;49:588–98.
- [8] Hermantin FU, Peters T, Quartararo L. A prospective, randomized study comparing the results of open discectomy with those of video-assisted arthroscopic microdiscectomy. *J Bone Joint Surg [Am]* 1999; 81:958–65.
- [9] Hijakata S, Yamgishi M, Nakayama T, et al. Percutaneous discectomy: a new treatment method for lumbar disc herniation. *J Toden Hosp* 1975;5:5–13.
- [10] Hijakata S. Percutaneous nucleotomy. A new concept technique and 12 years experience. *Clin Orthop* 1989;238:9–23.
- [11] Kafadar A, Kahraman S, Akboru M. Percutaneous endoscopic transforaminal lumbar discectomy: a critical appraisal. *Minim Invasive Neurosurg* 2006;49:74–9.
- [12] Kambin P. Arthroscopic lumbar intervertebral fusion. In: Frymoyer JW, editor. *The adult spine: principles and practice*, 2nd ed Philadelphia: Lippincott-Raven; 1997. p. 2037–46.
- [13] Kambin P. Arthroscopic microdiscectomy. *Arthroscopy* 1992;8:287–95.

- [14] Kambin P, Brager MD. Percutaneous posterolateral discectomy: anatomy and mechanism. *Clin Orthop* 1987;223:145–54.
- [15] Kambin P, O'Brien E, Zhou L, et al. Arthroscopic microdiscectomy and selective fragmentectomy. *Clin Orthop* 1998;347:150–67.
- [16] Kambin P, Savitz MH. Arthroscopic microdiscectomy: an alternative to open disc surgery. *Mt Sinai J Med* 2000;67:283–7.
- [17] Kambin P, Schaffer JL. Percutaneous lumbar discectomy: review of 100 patients and current practice. *Clin Orthop* 1989;238:24–34.
- [18] Lew SM, Mehalic TF, Fagone KL. Transforaminal percutaneous endoscopic discectomy in the treatment of far-lateral and foraminal lumbar disc herniation. *J Neurosurg (spine 2)* 2001;94:216–20.
- [19] MacNab I. Negative disc exploration: an analysis of the causes of nerve root involvement in sixty-eight patients. *J Bone Joint Surg [Am]* 1971;53:891–903.
- [20] Mathews HH. Transforaminal endoscopic microdiscectomy. *Neurosurg Clin N Am* 1996;7:59–63.
- [21] Mayer HM, Brock M. Percutaneous endoscopic discectomy: surgical technique and preliminary results compared to microsurgical discectomy. *J Neurosurg* 1993;78:216–25.
- [22] Mayer HM, Brock M. Percutaneous endoscopic lumbar discectomy (PELD). *Neurosurg Rev* 1993;16:115–20.
- [23] Schaffer JL, Kambin P. Percutaneous posterolateral lumbar discectomy and decompression with a 6.9-millimeter cannula: analysis of operative failures and complications. *J Bone Joint Surg [Am]* 1991;73:822–31.
- [24] Thongtrangan I, Le H, Park J, et al. Minimally invasive spinal surgery: a historical perspective. *Neurosurg Focus*. 2004;15:16, e13.
- [25] Yeung AT, Yeung CA. Advances in endoscopic disc and spine surgery: foraminal approach. *Surg Technol Int* 2003;11:255–63.
- [26] Yeung AT. The evolution of percutaneous spinal endoscopy and discectomy: state of the art. *Mt Sinai J Med* 2000;67:327–32.
- [27] Yeung AT, Tsou PM. Posterolateral endoscopic excision for lumbar disc herniation: surgical technique, outcome, and complications in 307 consecutive cases. *Spine* 2002;27:722–31.
- [28] Williams R. Microlumbar discectomy—a conservative surgical approach to the virgin herniated lumbar disc. *Spine* 1978;3:175–82.